NEVA 1st PASS in JENA UNIVERSITY

Clinical Case Report

Professor Thomas Mayer
Head of INR Department,
Jena University,
GERMANY

Presentation

55 year old stroke patient presented with hemiplegia and aphasia. Imaging confirmed a left MCA (M1) occlusion. The CBF map confirmed the existence of significant salvageable penumbra in the occluded area.

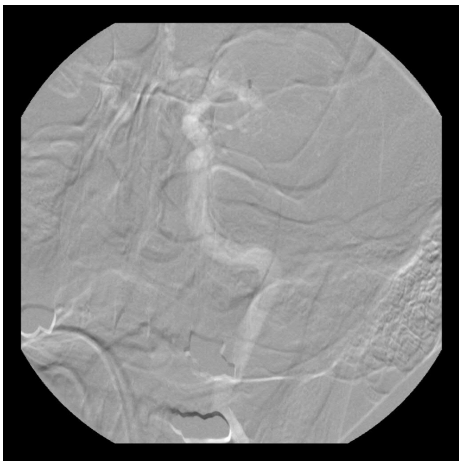

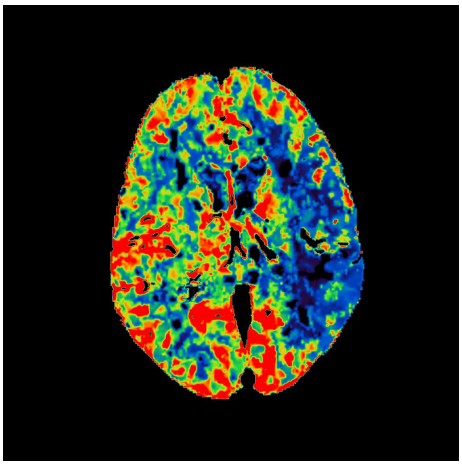

The Procedure

Professor Mayer and his team decided to do thrombectomy with a NeVa M1 under distal aspiration and got the clot out in a single pass.

Access to the occlusion

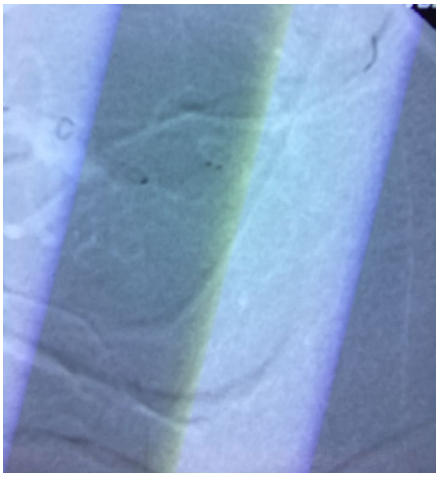

NeVa M1 deployed in the MCA

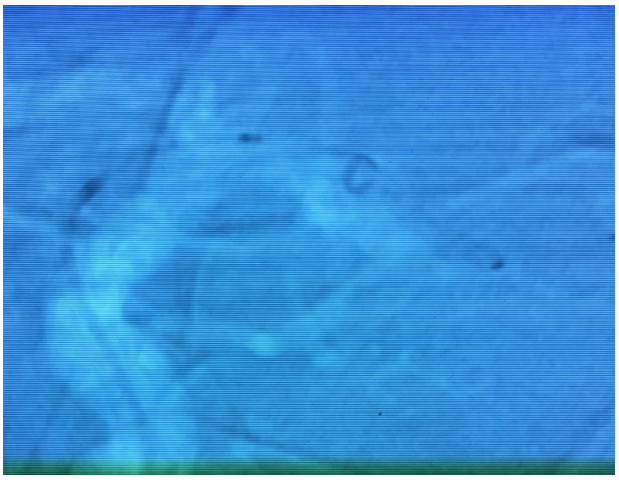

First pass retrieval with the NeVa basket partially collapsed in the distal access/aspiration catheter

NeVa basket with incorporated clot after the first pass

The resulting recanalization was a TICI 2C, achieved in just under 15 minutes from groin puncture.

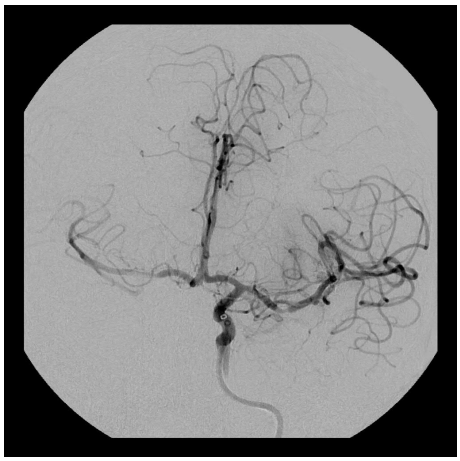

CTA (AP) AFTER first pass with NeVa: TICI 2C

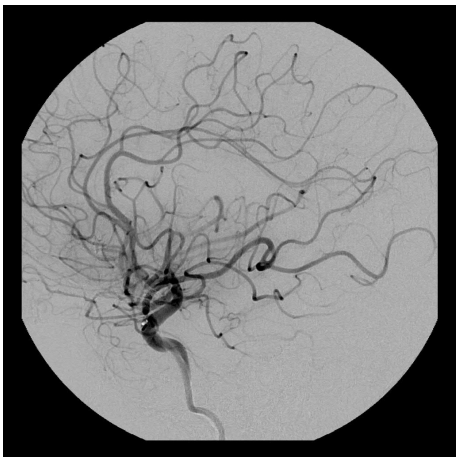

CTA (Lateral) AFTER first pass with NeVa: TICI 2C

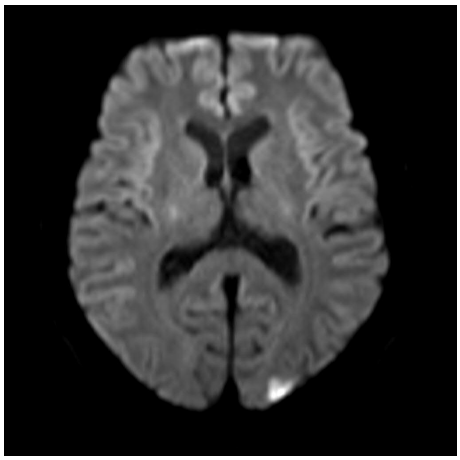

Diffusion-MR the day after the procedure showing minor infarct

Before:
Blocked M1
Hemiplegia & Aphasia at Onset

CTA (AP) BEFORE recanalization attempt with NeVa

After:
TICI 2C at first pass
No symptoms at 24 hours

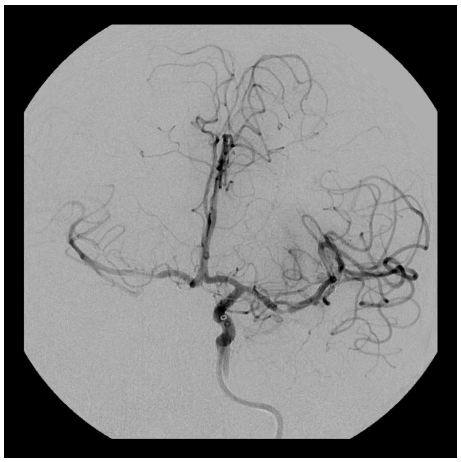

CTA (AP) AFTER first pass with NeVa: TICI 2C

Clinical success

Since the patient had presented very early after the onset of symptoms and hardly had any ischemic core on his CT, an excellent recovery was possible with no symptoms at 24 hours.

At VESALIO, we feel blessed to be part of the stroke field where together with these dedicated physicians, we can make an incredible impact on people's lives.

Thank you Jena!

Andreas Schreiner, Prisma Plus, Vesalio partner in Germany, after the case